

Cotrimoxazole + an ACE inhibitor or ARB: sudden death

● Hyperkalaemia.



Cotrimoxazole, an antibiotic that combines *sulfamethoxazole* and *trimethoprim*, can cause hyperkalaemia (1).

Co-administration of *cotrimoxazole* with other drugs that can increase potassium levels, such as angiotensin-converting-enzyme (ACE) inhibitors and angiotensin II receptor blockers (ARBs, alias sartans), can lead to severe hyperkalaemia with a risk of cardiac arrhythmia (1).

In late 2014, a Canadian team published the results of a complex case-control study involving 1110 case patients aged 66 years or older who were taking an ACE inhibitor or an ARB and who died suddenly within 7 days after receiving an antibiotic prescription for urinary tract infection. They were compared with controls with various similar characteristics, but who survived after taking one of the same antibiotics (1). The antibiotic in question was *cotrimoxazole* in 288 cases. The risk of death within 7 days was statistically significantly higher with *cotrimoxazole* than with *amoxicillin* (relative risk 1.83; 95% confidence interval 1.5 to 2.2). *Amoxicillin* was chosen as the comparator because it is not known to cause cardiac disorders or hyperkalaemia (2).

A second analysis focusing on the 14-day period after antibiotic prescription provided similar results (2).

Compared to the control group, there was an excess of three sudden deaths per 1000 *cotrimoxazole* prescriptions (2).

Co-administration of two or more drugs known to cause hyperkalaemia can have fatal adverse effects. Practitioners should be aware of these drugs (including *cotrimoxazole*), avoid their co-administration, and carefully monitor serum potassium levels if co-administration is unavoidable.


©Prescrire

Selected references from Prescrire's literature search.

- 1- Prescrire Rédaction "Fiche B2. Hyperkaliémies médicamenteuses en bref" *Rev Prescrire* 2014; 34 (374 suppl. interactions médicamenteuses).
- 2- Fralick M et al. "Co-trimoxazole and sudden death in patients receiving inhibitors of renin-angiotensin system: population based study" *BMJ* 2014; 30: 349, g6196: 7 pages.

Galantamine: serious skin reactions

● A decidedly bad drug.



In November 2014, the Canadian regulator Health Canada announced that serious skin reactions, namely Stevens-Johnson syndrome and acute generalised exanthematous pustulosis, had been reported in patients treated with *galantamine*, a cholinesterase inhibitor used in Alzheimer's disease. Other less serious skin reactions were also reported (1).

The serious adverse effects of *galantamine*, including gastrointestinal, cardiac, neuropsychiatric and now cutaneous disorders, are disproportionate to its minimal and transient efficacy in Alzheimer's disease.

©Prescrire

Selected references from Prescrire's literature search.

- 1- Health Canada "Reminyl ER (galantamine hydrobromide) - New safety information regarding the risk of serious skin reactions - For health professionals" 18 November 2014. healthycanadians.gc.ca: 2 pages.

Topiramate: visual field defects

● Regular warning is needed.



Topiramate, a carbonic anhydrase inhibitor used in epilepsy, is known to have ocular adverse effects which include acute myopia and glaucoma (1).

In late 2014, the Australian regulatory agency warned of a risk of visual field defects with *topiramate* (2), occurring in patients without elevated intraocular pressure (1). The visual field defects were reversible in most patients whose outcome was known (2).

For example, a 22-year-old man who had been taking *topiramate* 100 mg/day for 7 months for seizure control, and a 21-year-old woman who had been taking *topiramate* 150 mg/day for about a year for seizures, lost part of their peripheral vision; both patients had marked improvement in their visual field defects after *topiramate* discontinuation (3).

Other antiepileptic drugs, including *pregabalin* and *vigabatrin*, are also known to cause visual field defects (1).

Topiramate has many adverse effects. Some, such as these visual field disorders, can be difficult to identify. As visual field defects can lead to accidents, patients must be informed of this risk during regular reassessment of the harm-benefit balance of their ongoing *topiramate* therapy.

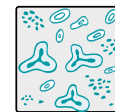
©Prescrire

Selected references from Prescrire's literature search.

- 1- Prescrire Rédaction "12-1. Patients épileptiques" *Rev Prescrire* 2014; 34 (374 suppl. interactions médicamenteuses).
- 2- Therapeutic Goods Administration "Topiramate and visual field defects" *Medicines Safety Update* 2014; 5 (6): 203.
- 3- Mandal A et al. "Ocular adverse effects of topiramate: two case reports" *Indian J Pharmacol* 2008; 40: 278-280.

Cotrimoxazole: fatal thrombocytopenia

● Hypersensitivity.



Cotrimoxazole, a combination of the sulfonamide antibiotic *sulfamethoxazole* and the antifolate antibiotic *trimethoprim*, exposes patients to the risk of haematological disorders, including thrombocytopenia. This is one type of hypersensitivity to *cotrimoxazole*, which also causes hypersensitivity reactions affecting other organs (1).

In late 2014, Health Canada had received 130 reports of thrombocytopenia in patients taking *cotrimoxazole*. In over half of these cases, platelets were the only blood lineage affected. Twelve patients died (2).

Many drugs other than *cotrimoxazole* can cause potentially severe thrombocytopenia (3). When thrombocytopenia occurs, the possibility of a drug-related cause should be investigated, and discontinuation of the suspected drug or drugs should be considered.

©Prescrire

Selected references from Prescrire's literature search.

- 1- Prescrire Rédaction "16-1-12. Patients sous sulfaméthoxazole + triméthoprime" *Rev Prescrire* 2014; 34 (374 suppl. interactions médicamenteuses).
- 2- Health Canada "Summary Safety Review - Sulfamethoxazole-trimethoprim - risk of drug-induced immune thrombocytopenia" 18 November 2014: 2 pages.
- 3- Prescrire Rédaction "Thrombopénies isolées dues au médicament" *Rev Prescrire* 2000; 20 (204): 204.